

- As the inner foreskin separates from the glans, some areas may remain attached. These attachments are called **adhesions**. Most boys will have adhesions at some time. As the inner foreskin continues to separate, these adhesions usually break down on their own. By the age of 17, they should have all disappeared. The adhesions should not be forcefully broken down – time and normal exploratory behaviour will take care of them as your child ages.
- It is not unusual for some boys with incompletely retractable foreskins to have **ballooning of the foreskin** when they void. This does not require treatment if the child is otherwise voiding without difficulty.
- Persistent narrowing of the foreskin tip preventing retraction after the age at which it should normally come back easily is called **phimosis**. This may be the result of delayed maturation or scarring of the Phimotic ring. In some cases, the foreskin will soften up and become retractable with the use of a steroid ointment. In others, circumcision may be necessary.

The foreskin is a normal part of your child's anatomy. With proper care and understanding of its natural development, foreskin problems can be avoided.

## Foreskin care for boys

The foreskin is the sheath of thin skin that normally covers and protects the head of the penis.



*This publication is produced by*



Canadian  
Urological  
Association

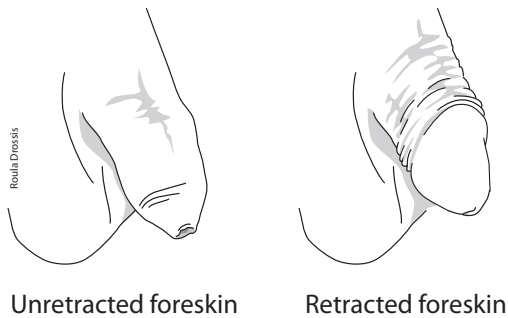
*The Voice of Urology in Canada*

The information in the publication is not intended to convey medical advice or to substitute for direct consultation with a qualified medical practitioner. The Canadian Urological Association disclaims all liability and legal responsibility howsoever caused, including negligence, for the information contained in or referenced by this brochure.

© 2014. Canadian Urological Association. All rights reserved.

15E-FORE-06-09

The foreskin (or prepuce) is the sheath of thin skin normally covering the head of the penis (glans). The inner foreskin is attached to the penile shaft just beyond the glans, with a small band (the frenulum) approaching the opening of the urinary passage (urethral meatus) on the undersurface. Its function and natural development must be understood to ensure proper care.



The foreskin protects the glans and urethral meatus in the diapered baby, preventing irritation from contact with urine. In older boys and men, the foreskin continues to protect the sensitive glans. The foreskin may also have specific functions related to sensation and immunity.

At birth, the inner foreskin is often fused to the glans and the opening at the tip of the foreskin may be narrow. This prevents it from being pulled back or retracted to uncover the glans. Normal urination should not be affected. As your child matures, the inner foreskin will gradually separate from the glans and the narrow tip will widen, allowing progressive retraction. The foreskin should never be retracted forcefully.

The age at which the foreskin becomes completely retractable is quite variable. By three years, most boys can retract their foreskin at least partially. Only 1-2% of boys are still not able to retract their foreskin by the age of seventeen.

**Circumcision** is the surgical removal of the foreskin. Some parents chose to have their sons circumcised for social, cosmetic or ritual reasons. In others this operation is necessary due to problems with the foreskin. Routine circumcision of newborn boys, once very popular, is now much less common. Several medical organizations have discouraged routine circumcision after considering the risks and benefits of this surgery.

## Care of the normal foreskin

The uncircumcised penis requires no special care. It can be kept clean with a gentle soap and warm water wash daily. No attempt should be made to retract the foreskin until it can be pulled back with ease. Then, your son should be taught to pull his foreskin back gently to clean its inner surface and the glans with soap and water. It should be thoroughly rinsed with water before being dried with a towel. After retraction, the foreskin must always be brought back to its usual position covering the glans.

**It is important not to retract the foreskin forcefully** for any reason. Some parents feel the need to pull the foreskin back to “clean under it”. Since the young boy’s inner foreskin and the glans are initially fused, there is no space to clean.

Forceful retraction also may lead to cracking and bleeding of the tip of the foreskin. Over time, this may cause scarring of the skin making retraction impossible. Circumcision may then be necessary.

## Possible problems

Occasionally, a problem with the foreskin may require medical attention.

- All over the body, skin cells are shed continuously as they die off and are replaced by new ones. This turnover usually occurs without notice. Cell replacement also takes place on the inner foreskin and glans. When the foreskin is not yet retractable, the dead skin cells may build up into soft, yellow or white lumps apparent under the skin. This is called **smegma**. This buildup is a natural and harmless process that may help separate the foreskin from the glans. The smegma will eventually work its way out as the foreskin becomes retractable.
- In some boys, the foreskin may be retractable even if the tip is a bit narrow. If the foreskin is replaced over the glans shortly after your child voids or bathes, this narrowing should not cause any trouble. In time the tight area should stretch and disappear. However, if your child leaves the foreskin retracted, this narrow ring may become trapped behind the glans causing pain and swelling of the penis. This is called a **paraphimosis**. Medical attention should be sought promptly so that the foreskin can be put back in the normal position.
- In the diapered baby, irritating substances in the urine may cause **inflammation** with redness and swelling of the foreskin. Inflammation can be managed simply with more frequent diaper changes, the application of antibiotic ointment (e.g. Polysporin™) to the foreskin tip and regular bathing. In some cases the entire penis may become red, swollen and tender (**balanitis**). In this case, the child should be seen by a doctor who may prescribe a course of oral antibiotics.